

Bovine bone granulate or autogenous block grafts in maxillofacial reconstructions*

Material ksenogeny lub kość autogenna w rekonstrukcjach szczękowo-twarzowych*

Paweł Zawadzki¹, Michał Jonasz¹, Dariusz Rolski²

¹ Department of Cranio-Maxillofacial Surgery, Oral Surgery and Implantology, Medical
University of Warsaw

Head: dr. n. med. P. Zawadzki

² Department of Prosthodontics, Medical University of Warsaw

Head: prof. E. Mierzińska-Nastalska

KEY WORDS:

bone substitute materials, autogenous bone, bone
grafting, alveolar bone regeneration, alveolar
bone remodeling, alveolar bone grafting

HASŁA INDEKSOWE:

materiały kośćcozastępcze, kość autogenna, prze-
szczep kości, regeneracja kości wyrostka zębo-
dołowego, zanik kości wyrostka zębodołowego,
przeszczepianie kości wyrostka zębodołowego

Summary

Nowadays biotechnology can offer vast opportunities for maxillofacial surgery. The new prostheses and individual face implants can be produced at the chairside. A great problem for dental and maxillofacial surgeon is the reconstruction of lost bone. Bone loss may be caused by resorption, trauma or resection after surgical treatment of tumours. Rehabilitation of the majority of these patients requires a bone graft. Lack of general protocol and a multitude of materials used to rebuild bony tissue often makes it difficult to choose the best method.

In the present study, xenograft of bovine bone granulate (applied with collagen membrane) has been compared with autogenous bone graft. The statistical analysis was performed to compare the level of bone loss following these procedures with a possibility of introducing dental implants in reconstructed tissue.

A total of 41 patients (26 women and 15 men) underwent reconstruction in 62 treatment sites. 13

Streszczenie

Obecne zdobycze biotechnologii otwierają nowe możliwości dla chirurgii szczękowo-twarzowej. Protezy i indywidualne implanty mogą być wytwarzane przez samych lekarzy. Dużym wyzwaniem dla chirurgów stomatologów i szczękowo-twarzowych jest rekonstrukcja utraconej tkanki kostnej. Utrata kości może być spowodowana przez jej resorpcję, uraz lub usunięcie z powodu guza nowotworowego. Rehabilitacja u większości tych pacjentów wymaga przeszczepu kości. Brak ogólnego protokołu postępowania i mnogość materiałów stosowanych do odbudowy tkanki kostnej utrudnia wybranie jednej, najlepszej metody leczenia.

W obecnym badaniu porównywano przeszczep ksenogeny w postaci granulatu (stosowany wraz z błoną zaporową) z kością autogenną. Wykonano analizę statystyczną dla porównania poziomu utraty kości po przeprowadzonych zabiegach oraz oceny możliwości pograżenia implantów w rekonstruowanej kości.

* Scientific study was financed from the educational budget for years 2010-2013 as a research project.

* Praca wykonana w ramach projektu badawczego ze środków uczelni przyznanych na lata 2010-2013.

reconstructions were performed with bovine bone xenograft and 49 with autogenous bone graft. The level of bone loss was lower in cases where bovine bone substitute material was applied, and thus gave better possibility to perform dental implant treatment.

Dokonano rekonstrukcji kości w 62 miejscach zabiegowych u 41 pacjentów (26 kobiet i 15 mężczyzn). Wykonano 13 rekonstrukcji z użyciem materiału ksenogennego i 49 z użyciem kości własnej pacjenta. Poziom zaniku kości był mniejszy w miejscach gdzie użyto materiału kośćcizastępczego, co stworzyło lepsze warunki dla leczenia implanto-protetycznego.

Introduction

Possibilities of the alveolar process reconstructions are currently the subject of numerous discussions and deliberations. There is no single coherent protocol for such treatment, and a multitude of methods and materials used for the reconstruction of bony tissue often makes it difficult to determine the optimal treatment plan.

Bone loss may be due to atrophy, past injury or partial bone resection resulting from treatment of tumours. Rehabilitation of the majority of these patients requires a reconstruction by means of the bone graft to restore the masticatory function.

In the international literature, there are numerous reports concerning the possibilities of augmentation of the alveolar process. The main topic of interest is the process of healing and graft integration. It analyzes the degree of reconstructed bone loss and possibility of dental implants placement after augmentation.

The development of tissue engineering and biotechnology and their application to dental and maxillofacial surgery offers new opportunities and promising perspectives for the use of advanced biomaterials. Their use is not always clear when it comes to therapeutic results and their potential applications require continuous research.

The aim of the study is to assess the reconstructed bone loss after using granular

bovine bone xenograft or an autogenous bone graft.

Material and methods

The study included healthy individuals who required reconstruction of the alveolar bone in height and/or width, treated in 2010-2014 at the Department of Cranio-Maxillofacial, Oral Surgery and Implantology, Medical University of Warsaw. Patients with cleft palate, pregnant or breastfeeding, and tobacco smokers were excluded.

The patients received written information about the study and a consent form for the participation in the study, approved by the Bioethics Committee of the Medical University of Warsaw (MB/74/2010).

Bone reconstructions were performed in 62 areas of jaws in 41 patients (26 women and 15 men). The causes of bone loss were atrophy due to tooth loss – 50, trauma – 9 or reconstruction after tumour resection – 3 recipient places. Average age was 37 years, the youngest participant in the study was 17 years old and the oldest 66. The average age for men was 33 years and for women 39 years. 15 patients did not exceed 30 years of age. In the 49 treated areas patient's own bone was used, and in 13 cases a xenograft. Bone reconstruction was carried out in 44 areas in the maxilla and 18 in the mandible.

CT scans were performed before, the day after

and 3 months after bone reconstruction surgery. A total of 121 CT studies were performed, in which the alveolar bone at 2125 points was measured. 421 measurements were made in long axis, and 1,704 times the width of the alveolar ridge was measured.

The treatment plan was discussed in detail with each patient. The available methods for reconstruction of bone defects as well as available materials were presented. Reconstructed area and the approximate volume of bone graft were imaged on the CT. The pros and cons of each method and the risks associated with surgery were discussed. The patient received thorough oral hygiene instructions and recommendations for nutrition after surgery.

Patients were informed of the approximate time of hospitalization and healing of the graft, as well as the possibilities of subsequent implant treatment.

Inclusion criteria

Patients enrolled for the study were generally healthy, diagnosed with bone defect, or had the resection of the alveolar process tumour planned. In patients with post-traumatic defects and atrophy, the area and extent of augmentation was chosen on the basis of dental implant treatment plan. Bone reconstruction was performed to enable the subsequent submergence of dental implants. Patients undergoing tumour surgery had their mandible reconstructed in order to preserve the masticatory system.

Exclusion criteria

The study excluded patients who were:

- diagnosed with a disease of the circulatory system,
- taking drugs which compromised clot formation,
- diagnosed with osteo-articular disease,
- taking bisphosphonates,
- diagnosed with diabetes,
- after radiotherapy or chemotherapy,
- smokers,

- alcoholics,
- diagnosed with lesions on mucous membranes of the oral cavity,
- using mobile prosthetic restorations based on the mucous membrane in the area of the planned reconstruction.

Surgeries were performed after antibiotics administration. The procedure was initiated by recipient site preparation - reflecting the flap, bone atrophy evaluation or elevation of the mucous membrane of the maxillary sinus. Then bone from the donor area was harvested and shaped to enable adhesion to the entire surface of the defect, and fixed with osteosynthesis screws. Bone graft edges were smoothed to remove sharp edges. Mucoperiosteal flap was mobilized by cutting the periosteum and double-layer, no tension sewing was performed. Finally, the donor site was sutured. In areas where the xenograft reconstruction was planned, its proper amount was applied to obtain a desired volume of bone. Then it was covered with a collagen membrane and the flap was sutured as above.

Cone Beam Computed Tomography (CBCT) examinations were performed before treatment, after treatment and three months after surgery¹ in order to assess the amount of reconstructed bone and the percentage of its loss during healing. CT examination was performed by the same person using the same device - Newton VG. Image analysis and bone measurements were carried out in the NNT software.

The patient's head was positioned in the device in a reproducible manner. The same bracket for the lower jaw was always used and forehead support was set at the height of the point of glabella. Laser pointers of the vertical and horizontal lines enabled correlation with the patient's head position in sagittal and horizontal plane.

Radiological image analysis was initiated by choice of the area occupied by maxilla and mandible. Measurements were made on vertical

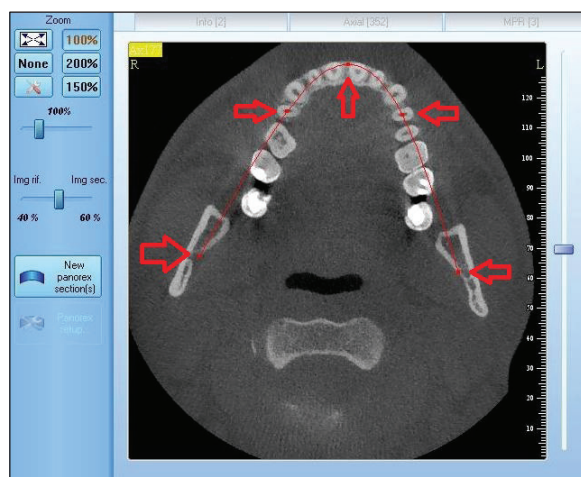


Fig. 1. CBCT scan – reference points for the curve.

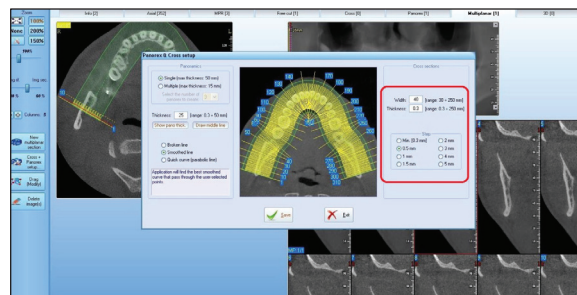


Fig. 2. CBCT scan – cross-sections parameters.

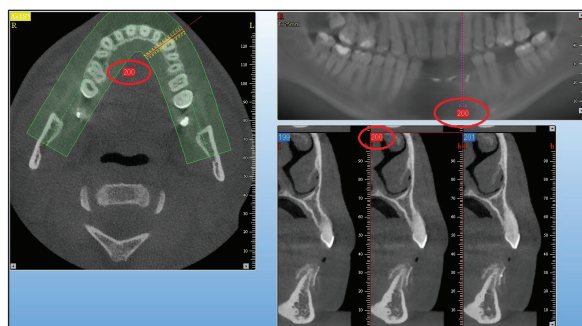


Fig. 3. CBCT scan – vertical section number selected.

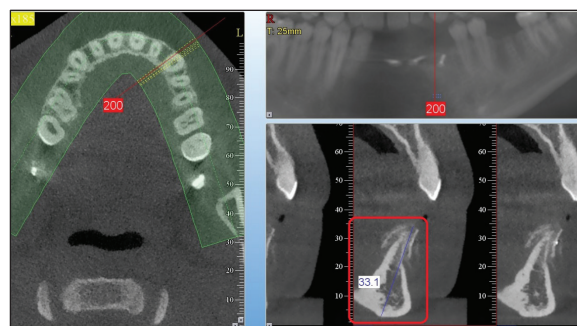


Fig. 4. CBCT scan – measurement of the long axis.

sections of the curve, which was created along the alveolar ridge, similar to the panoramic picture.

Reference points were the mandibular foramina, first premolars (if absent, the closest mesial tooth) and central line (Fig. 1).

Cross section of 40 mm in width and a 0.3 mm thickness were generated every 0.5 mm along the curve (Fig. 2).

Section height included the area occupied by the maxilla and the mandible - individual for each patient. The measurements were performed by the same person with 200% magnification. Analyzed area was marked by the number of cross-section.

Then the number of vertical section in the area of the bone defect was determined (Fig. 3).

First, the measurements of the long axis of

the ridge were made, from the top to the base (Fig. 4).

Then the axis perpendicular to the long axis was determined and the width of the reconstructed area was measured according to the perpendicular one.

Width measurements were performed on top of the ridge (up to 1 mm) – point 0 (Fig. 5), 5 mm from the top - point 5 and 10 mm from the top - point 10 (Fig. 6).² In one reconstructed area the cross sections were analyzed at every 5 mm.

Each measurement was placed in a table characterizing the individual patient and the CT study (preoperative, postoperative and after 3 months of treatment).

In the CT scans, 3 months postoperatively, the possibility of placing the implant in the

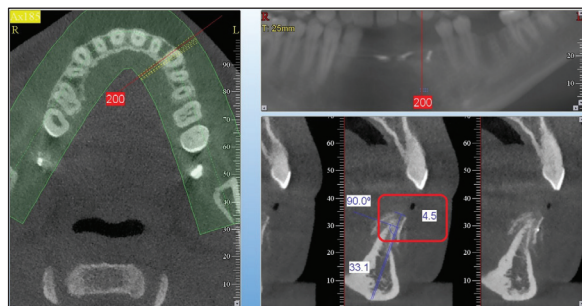


Fig. 5. CBCT scan – width measurement at the 0 point.

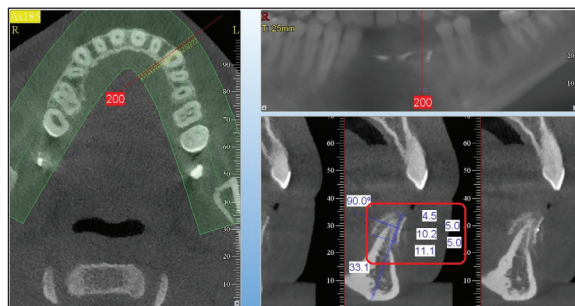


Fig. 6. CBCT scan – width measurements at points 0, 5 and 10.

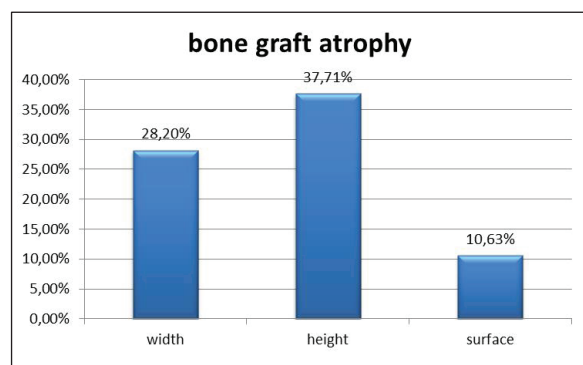


Fig. 7. Mean percentages of bone graft atrophy.

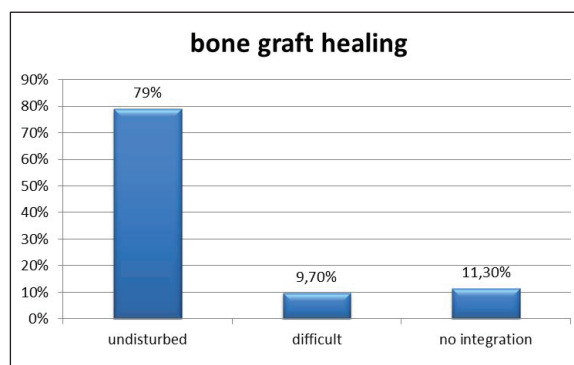


Fig. 8. Healing bone grafts.

reconstructed area was assessed. As for the criteria, it was obligatory that the minimum ridge width was 2 mm larger than the width of the planned implant³ and ridge height was 2 mm greater than the distance from the alveolar crest to the anatomical structures preventing implantation, ie. the inferior alveolar nerve⁴ or the maxillary sinus. The possibility of placing dental implant was one of the measures of the success of reconstructive treatment.

Results

In the analyzed clinical material an average 2.97 mm of bone was reconstructed in the vertical dimension and 3.05 mm in the horizontal dimension. On average, 9.0585 mm² of bone was reconstructed. Average reconstructed bone atrophy: 1.12 mm in height (37.71%), 0.86 mm in width (28.2%) and 0.9632 mm² of cross section field (10.63%) (Fig. 7).

Healing proceeded correctly in 79% of cases. Healing was difficult in 9.7% of cases, and 11.3% of the grafts did not integrate (Fig. 8). The process of healing was not statistically significant according to the cause of the defect as well as no significant differences were observed if grafts were placed in the maxilla or the mandible.

In 72.4% of the reconstructed areas implantation was possible. Healing after bone reconstruction was statistically significant to the possibility of placing an implant. In contrast, the prognosis of implant treatment was of no difference if the reconstruction was carried out in the maxilla or the mandible.

Statistical analysis was performed using STATISTICA 8.0 software. In the process of hypotheses testing the level of significance was set at $p=0.05$ and two-sided critical region was assessed. P-values ≤ 0.05 were stated below tables (Table 1).

Table 1. Variables used in the statistical survey

No.	Variable	variable description
1	sex	1 = female 2 = male
2	age	age of the patient on the day of surgery (years)
3	the cause of bone cavity	1 = atrophy 2 = trauma 3 = tumour
4	reconstructive material	1 = autogenous bone 2 = bone substitute material
5	recipient region	1 = maxilla 2 = mandible
6	evaluation of healing	1 = no integration 2 = difficult 3 = undisturbed (after a week)
7	the possibility of implantation	0 = no 1 = yes (after 3 months)
8	long axis before surgery	(mm)
9	width 0 before surgery	(mm)
10	width 5 before surgery	(mm)
11	width 10 before surgery	(mm)
12	long axis after surgery	(mm)
13	width 0 after surgery	(mm)
14	width 5 after surgery	(mm)
15	width 10 after surgery	(mm)
16	long axis after 3 months	(mm)
17	width 0 after 3 months	(mm)
18	width 5 after 3 months	(mm)
19	width 10 after 3 months	(mm)

Analysis of interdependence of discrete variables.

The analysis was based on the construction of contingency tables and calculation of Pearson chi-square independence test. For four-pole tables which did not meet the theoretical requirements of chi-square test, Fisher's exact test was calculated. In a situation where there was a significant relationship between the variables Wanke's surpluses were calculated (Table 2, 3, 4).

Table 2. Discrete variables distributions

	n	%
Sex		
1 female	41	66.1
2 male	21	33.9
The cause of defect		
1 atrophy	50	80.6
2 trauma	9	14.5
3 tumour	3	4.8
Reconstructive material		
1 autogenous bone	49	79.0
2 bone substitute material	13	21.0
Recipient region		
1 maxilla	44	71.0
2 mandible	18	29.0
Healing		
1 no integration	7	11.3
2 difficult	6	9.7
3 undisturbed	49	79.0
Possibility of implantation		
0 not	16	27.6
1 yes	42	72.4

T a b l e 3. The relationship between the type of reconstructive material used (reco.m.) and the possibility of implantation (pos.imp.) (three patients after tumour and a patient who did not present were excluded)

	pos.imp.	1	2	n	%
		reco.m.	reco.m.		
Number	0	16	0	16	27.59%
% of column		34.78%	0.00%		
% of row		100.00%	0.00%		
Wanke		1.26	0.00		
Number	1	30	12	42	72.41%
% of column		65.22%	100.00%		
% of row		71.43%	28.57%		
Wanke		0.90	1.38		
Number	Total	46	12	58	
%		79.31%	20.69%		100.00%

chi-square = 5.764, df = 1, p = 0.0164; Fisher p = 0.0251.

Interpretation: There is a significant relationship between the reconstructive material used and the possibility of implantation.

T a b l e 4. Relationship between the type of material used (m.reko) and healing (healing)

	healing	1	2	n	%
		reco.m.	reco.m.		
Number	1 + 2	13	0	13	20.97%
% of column		26.53%	0.00%		
% of row		100.00%	0.00%		
Wanke		1.27	0.00		
Number	3	36	13	49	79.03%
% of column		73.47%	100.00%		
% of row		73.47%	26.53%		
Wanke		0.93	1.27		
Number	Total	49	13	62	
%		79.03%	20.97%		100.00%

chi-square = 4.364, df = 1, p = 0.0367; Fisher p = 0.0526, Fisher (1) p = 0.0316.

Interpretation: When bone substitute material was applied the healing was better.

Measurements made on vertical cross-sections at computed tomography studies allowed for a quantitative assessment of reconstructions. The differences between the measurements of the long axes and fields of the cross sections before surgery, after surgery and three months after surgery showed statistical significance.

The difference in the measurements made three months after surgery, and measurements made within a week after the procedure determined the level of grafted bone loss. Statistical significance was shown in measurements both in long axis and in the width at the top of the ridge, 5 mm from the top and 10 mm from the top of the ridge. The average reconstructed bone resorption in width and in field was also significant.

Gender, age of the patient and cause of bone defect had no influence on the resorption of the reconstructed bone.

Differences in bone loss were also observed depending on the reconstructive material applied. In areas where the autogenous bone was used resorption was greater.

Recipient site was also taken into consideration. The only measurements to be statistically significant were those of 10 mm in width from the top of the ridge. In this area the reconstructed bone loss proved to be smaller if the reconstruction was performed in the mandible. Other measurements did not show statistically significant differences when considering grafting within the maxilla or the mandible.

Discussion

Reconstruction of the alveolar bone of the jaws is a broad topic. It involves many areas of biology and medicine, ranging from surgical techniques, through the individual treatment planning up to the issues of biotechnology. An increasing number of publications in this

field show great interest in alveolar bone reconstructions with patients demanding maximally predictable and minimally invasive procedures.

Research in PubMed based on the keywords like “alveolar bone augmentation” and “human” returned 859 publications only in the past 5 years. Among these works, the most common reports were case reports – 235. 153 publications were clinical trials, 146 – comparative studies, 18 – controlled clinical trials, and 9 – meta-analyses.

In the present study, an average of 2.97 mm of bone in the vertical dimension and 3.05 mm in the horizontal dimension was reconstructed. The average bone loss observed was 28.2% in width and 37.71% in height. *Tulasne et al.* conducted their review of the literature concerning the reconstruction of the alveolar bone in lateral mandible and calculated an average of 7.83 mm when reconstructing alveolus height, 7.16 mm when reconstructing in width and 6.7 mm vertically and 8.1 mm horizontally when reconstructing both in height and width.⁵ They assessed the percentage of unveiling the graft at 1.8%, and total or almost total resorption of the graft at 4.2%, which seems to be more favourable comparing to our study. *Haers et al.* evaluated the resorption of an autogenous bone graft at 20%.

No articles were found describing statistically significant effect of age, gender or cause of the bone defect (injury, atrophy or condition after tumour resection) on the grafted bone resorption, nor was the comparison of success rate of reconstructions carried out in the maxilla or the mandible. Our study did not reveal statistically significant differences between the healing of bone grafts applied in the maxilla or the mandible, either, and resorption proved to be significantly lower only at the basal part of the mandibular alveolar ridge.

Esposito et al. performed a meta-analysis of the literature in terms of the need for autogenous bone or bone substitute material grafting compared with the possibility of short implants placement.⁶ When the reconstruction in height was necessary, the placement of short implants showed significantly better prognosis. However, when the width was to be rebuilt, the two methods did not differ significantly. On the other hand, they showed a statistically significant difference when applying a tent technique with bone substitute material or autogenous bone harvested from linea oblique.⁷ When autogenous bone was applied, the resorption was 0.6 mm greater. In another study, which compared the autogenic and xenogenic bone blocks resorption, the greater bone loss was observed in autografts harvested from the iliac crest, but without statistically significant differences.⁸ In each patient, autogenous bone block on one side and a xenograft bone block on the opposite side was used to reconstruct in the posterior part of the mandible. Patients were also asked what type of reconstructive material they would prefer. 8/10 people would choose the bone substitute material, and 2 did not see any difference. *Esposito* et al. found that in the analyzed literature the number of cases was insufficient and the drawn conclusions still uncertain. They underlined the growing interest in bone grafts and reviewed a variety of augmentation techniques. They pointed out that it is important to consider the necessity of bone reconstruction when it is possible to apply short implants, which often allows avoiding risky and complicated procedures.

In these publications and literature reviews the possibility of implantation and prosthetic treatment after alveolar ridge augmentation was always taken into account. *Clementini* et al. conducted a review of the literature comparing the maintenance of implants submerged during a single-stage procedure

of augmentation and implantation with those submerged after the graft has integrated and remodeled.⁹ In six articles a single-stage surgery was described, in five publications – a double-stage one and two papers compared both methods. In the case of implantation performed during reconstructive surgery the success rate ranged from 61.5% to 100%, and in a two-step procedure 75%-98%.

Conclusions

In the areas reconstructed with bone substitute material implantation was statistically more often possible. If the bone substitute material was applied, fewer complications were observed during healing. Also reconstructed bone resorption was smaller.

However, not every area of the oral cavity requiring reconstruction allows the use of the bone reconstructive material. The choice of treatment plan always depends on the particular case and the area where the grafting is to be performed, as well as patient's preference and doctors experience.

References

1. *Krasny M, Krasny K, Kamiński A, Fiedor P*: Global maxillary ridge augmentation with frozen radiation-sterilised bone blocks followed by implant placement: a case report. Cell Tissue Bank 2014 May 13.
2. *Vera C, De Kok IJ, Reinhold D, Limpiphatanakorn P, Yap AKW, Tyndall D, Cooper L*: Evaluation of Buccal Alveolar Bone Dimension of Maxillary Anterior and Premolar Teeth: A Cone Beam Computed Tomography Investigation. Int J Oral Maxillofac Implants 2012; 27, 6: 1514-1519.
3. *Spiechowicz E*: Protetyka Stomatologiczna (Dental Prosthetics book). PZWL Warszawa 2013, edition 6.
4. *Gupta J, Ali SP*: Cone beam computed tomo-

- graphy in oral implants. *National J Maxillofac Surg* 2013; 4, 1: 2-6.
5. *Tulasn JF, Guiol J, Jebblaoui Y*: Reconstruction pré-implantaire du secteur mandibulaire postérieur [Pre-implant posterior mandibular reconstruction]. *Rev Stomatol Chir Maxillofac*. 2012; 113, 4: 307-321.
 6. *Esposito M, Grusovin MG, Felice P, Karatzopoulos G, Worthington HV, Coulthard P*: The efficacy of horizontal and vertical bone augmentation procedures for dental implants – a Cochrane systematic review. *Eur J Oral Implantol*., 2009; 2, 3: 167-184.
 7. *Fontana F, Santoro F, Maiorana C, Iezzi G, Piattelli A, Simion M*: Clinical and histologic evaluation of allogenic bone matrix versus autogenous bone chips associated with titanium-reinforced e-PTFE membrane for vertical ridge augmentation: a prospective pilot study. *Int J Oral Maxillofac Implants* 2008; 23: 1003-1012.
 8. *Felice P, Marchetti C, Piattelli A, Pellegrino G, Checchi V, Worthington H, Esposito M*: Vertical ridge augmentation of the atrophic posterior mandible with interpositional block grafts: bone from the iliac crest versus bovine anorganic bone. Results up to delivery of the final prostheses from a splitmouth, randomised controlled clinical trial. *Eur J Oral Implantol* 2008; 1: 183-187.
 9. *Clementini M, Morlupi A, Agrestini C, Barlattani A*: Immediate versus delayed positioning of dental implants in guided bone regeneration or onlay graft regenerated areas: a systematic review. *Int J Oral Maxillofac Surg* 2013; 42, 5: 643-650.
- Zaakceptowano do druku: 16.02.2017 r.
Adres autorów: 02-005 Warszawa, ul. Lindleya 4 bl.4.
© Zarząd Główny PTS 2017.